

# AMERICAN ACADEMY OF PEDIATRICS

Committee on Genetics

Section on Endocrinology

Section on Urology

## Evaluation of the Newborn With Developmental Anomalies of the External Genitalia

**ABSTRACT.** The newborn with abnormal genital development presents a difficult diagnostic and treatment challenge for the primary care pediatrician. It is important that a definitive diagnosis be determined as quickly as possible so that an appropriate treatment plan can be established to minimize medical, psychological, and social complications. The purpose of this review is to identify which newborns among those with abnormal genital development need to be screened for intersexuality, to outline the investigations necessary, and to suggest indications for referral to a center with experience in the diagnosis and management of these disorders. An outline is also presented of the embryology of the external genitalia indicating where errors can arise to provide a framework for pediatricians to use when counseling families. Although the focus of this review is on newborns with what has been termed "ambiguous genitalia," it should be recognized that most genital abnormalities in newborns do not result in an ambiguous appearance. These anomalies include hypospadias, in which the genitalia are clearly malformed, although the sex is unquestionably male.

---

ABBREVIATION. CAH, congenital adrenal hyperplasia.

---

The birth of a child with ambiguous genitalia constitutes a social emergency. Because words spoken in the delivery room may have a lasting impact on parents and their relationship with their infant, it is important that no attempt be made to suggest a diagnosis or offer a gender assignment. The infant should be referred to as "your baby" or "your child"—not "it," "he," or "she." It is helpful to examine the child in the presence of the parents to demonstrate the precise abnormalities of genital development, emphasizing that the genitalia of both sexes develop from the same primordial fetal structures, that both incomplete development or overdevelopment of the external genitalia can occur, and that the abnormal appearance can be corrected and the child raised as a boy or a girl as appropriate. Parents should be encouraged not to name the child or register the birth, if possible, until the sex of rearing is established. As much as possible, the par-

ents need to be included in the discussions regarding sex of rearing. Each infant requires individual consideration based on physical examination, laboratory studies, and parental feelings. In many instances, transfer of the child to a tertiary care facility is necessary for optimal assessment. The emotional tone established by health care professionals in conveying this information can have a lasting influence on how the parents conceptualize the abnormal genital development. Therefore, a positive atmosphere is essential for parents to begin their relationship with their child.

### UNDERSTANDING SEXUAL DIFFERENTIATION

To explain to the family the cause of their newborn's genital abnormalities, the practitioner needs to understand the genetic and hormonal influences that are responsible for normal genital development. Before about 6 weeks' gestation, male and female embryos develop undifferentiated gonadal tissue and have primordial structures with the potential to produce either male or female genitalia. The genital appearance of the newborn is largely determined by the presence or absence of genetic and hormonal influences responsible for the active process of male differentiation. The fetus tends to develop as a female in the absence of these male influences. Intersex conditions arise because of an abnormality along the male pathway that interferes with complete masculinization or, in the case of a genetic female, some virilizing influence that acts on the developing embryo.

Male sexual differentiation is initiated by the *SRY* gene on the short arm of the Y chromosome. Under the influence of *SRY*, the undifferentiated gonad forms a testis, which produces the hormonal milieu that results in male sexual differentiation: testosterone stimulates the wolffian structures (epididymis, vas deferens, and seminal vesicles), and anti-Müllerian hormone suppresses the development of the Müllerian structures (fallopian tubes, uterus, and upper vagina). The conversion of testosterone to dihydrotestosterone occurs in the skin of the external genitalia and masculinizes the external genital structures. Most of this male differentiation takes place by about 12 weeks, after which the penis grows and the testes descend into the scrotum. In the absence of *SRY*, female sexual differentiation occurs. An error in

The recommendations in this statement do not indicate an exclusive course of treatment or serve as a standard of medical care. Variations, taking into account individual circumstances, may be appropriate.

PEDIATRICS (ISSN 0031 4005). Copyright © 2000 by the American Academy of Pediatrics.

genital morphogenesis may occur at any step in this developmental pathway.

### WHICH NEWBORNS NEED INVESTIGATION?

Infants whose genitalia are obviously ambiguous are investigated at birth so that sex of rearing can be assigned. In many cases, however, appearances are deceptive. For example, an infant with what appears to be bilateral cryptorchidism might be assumed to be a boy because of a normal-appearing phallic structure but in fact may be a girl with severe virilizing congenital adrenal hyperplasia (CAH). Similarly, an apparent female infant with only slight clitoral hypertrophy may be a genetic male with severe androgen insensitivity, necessitating eventual removal of the testicles to avoid malignant degeneration. It is necessary, therefore, to have well-defined clinical criteria for the investigation of intersexuality. To some extent these criteria are arbitrary insofar as even the mildest degree of hypospadias can be regarded as an example of incomplete masculinization. However, the incidence of an identifiable abnormality increases with the severity of the hypospadias<sup>1</sup> or when 1 gonad is also undescended.<sup>2</sup> The genital findings that warrant investigation for intersexuality are given in Table 1. Note that 3 of these findings are seen in infants who will initially be assumed to be boys, whereas another 3 arise in apparent girls. Only a minority of intersex patients have genitalia that are so ambiguous that the sex is uncertain.

These guidelines for investigation permit most newborns with an underlying intersex condition to be recognized promptly after birth. Other children with intersex disorders, however, may not be diagnosed until childhood or adolescence when virilization, premature pubarche or thelarche, or primary amenorrhea are investigated.

### THE HISTORY AND EXAMINATION

Evaluation begins with an obstetric history to include any evidence of endocrine disturbance during pregnancy. A family history should be sought of unexplained neonatal deaths or genital anomalies, abnormal pubertal development, or infertility in close relatives. The physical examination begins with a search for any features suggestive of a malformation syndrome. The external genitalia are then inspected to determine the degree of masculinization. The size of the phallus is assessed by rolling the corporeal bodies between the fingers to appreciate their true length and girth, as both ventral curvature

**TABLE 1.** Clinical Findings in a Newborn Infant That Raise the Possibility of Intersexuality

---

Apparent male
• Bilateral nonpalpable testes in a full-term infant
• Hypospadias associated with separation of the scrotal sacs
• Undescended testis with hypospadias
Indeterminate
• Ambiguous genitalia
Apparent female
• Clitoral hypertrophy of any degree
• Foreshortened vulva with single opening
• Inguinal hernia containing a gonad

---

(chordee), which is almost always present, and an abundance of prepubic fat often mask the true size of the penis. In full-term newborns the stretched penile length should measure at least 2 cm.<sup>3</sup> The extent to which the urogenital sinus has closed is then determined by identifying the position of the urethral meatus, which sometimes requires waiting until the baby voids. The fullness, symmetry, and rugosity of the labioscrotal folds are then noted. When these folds are asymmetrical, a gonad is frequently palpable on the more virilized side and is often associated with an inguinal hernia. An attempt should be made to palpate the gonads on each side by sweeping the examining fingers down along the line of the inguinal canal toward the labium or scrotum while the other hand grasps any possible gonad. This maneuver requires warm hands and considerable patience.

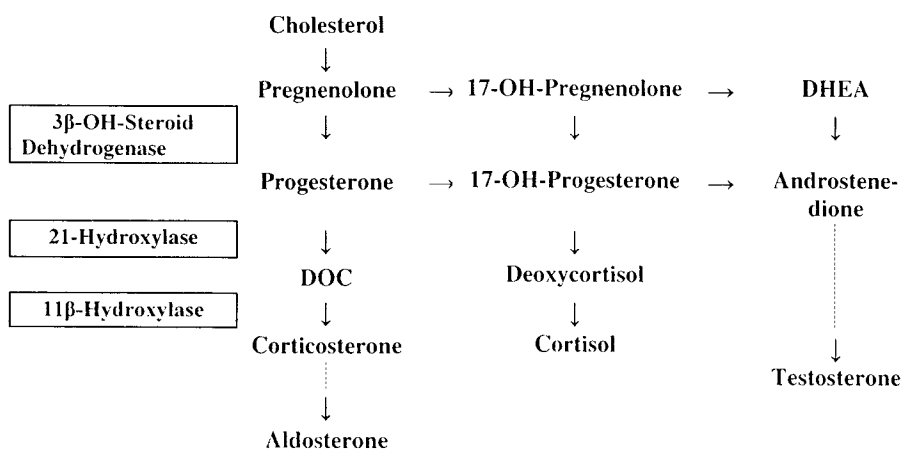
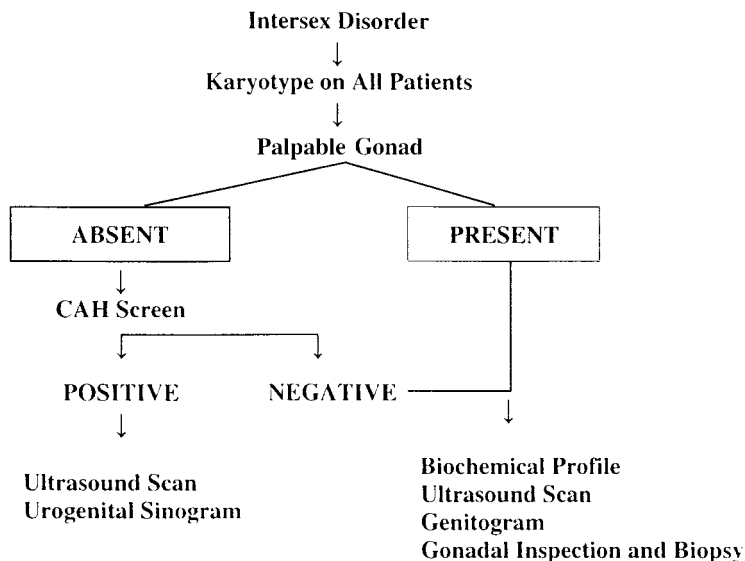
It is generally unwise at this stage to make a definitive diagnosis based on the physical findings alone, as the appearance of the external genitalia can vary widely, even among patients with the same underlying condition. There is only one deduction that can confidently be made, namely, that if a gonad is palpable the diagnosis is not a female infant with CAH in which the gonads are normal ovaries situated in the abdominal cavity. Some clues to help establish a diagnosis, however, may be found. For example, a well-developed phallus indicates that significant levels of circulating testosterone were present in utero, whereas asymmetry of the scrotum suggests the secretion of testosterone by the gonad on the better developed side. Other findings include dark skin pigmentation associated with high circulating levels of adrenocorticotrophic hormone, suggesting CAH, or a virilized appearance of the mother resulting from placental aromatase deficiency or a maternal endocrine tumor.

### LABORATORY AND IMAGING STUDIES

As CAH is the most common single cause of ambiguous genitalia in the newborn, a biochemical screen for this disorder should be performed in infants with symmetrical masculinization and nonpalpable gonads (Fig 1). Although the levels of 17-hydroxyprogesterone and androstenedione are greatly elevated in classic 21-hydroxylase deficiency, a more extensive panel is recommended so that the rarer forms of CAH are not overlooked (Fig 2). The infant's serum electrolyte levels should be determined immediately and followed closely until a diagnosis and treatment plan are established. Chromosome analysis should also be performed as an initial investigation. Results can usually be obtained within 72 hours by standard techniques or more rapidly by using a fluorescence in situ hybridization study. When the diagnosis of CAH is confirmed, further diagnostic testing is not necessary.

When 1 or both gonads are palpable or the CAH screen is negative, it is necessary to investigate further, including a pelvic ultrasound examination to identify a muscular uterine body and a genitogram to identify a vagina, a uterine canal, 1 or 2 fallopian tubes, or the vasa deferentia. A biochemical panel is also required to identify a block in testosterone bio-

**Fig 1.** Laboratory and imaging studies in newborns with intersex disorders.



**Fig 2.** Pathways of adrenal hormone synthesis.

synthesis, decreased 5- $\alpha$  reductase activity, or androgen insensitivity. If the results of these investigations do not identify a definitive diagnosis, the appropriate sex of rearing may nevertheless be obvious. However, at some point, inspection and biopsy of the gonads become necessary to establish the diagnosis. These in-depth investigations are usually done at a center that specializes in the diagnosis and management of these disorders.

### THE CAUSES OF AMBIGUOUS GENITALIA

Over the past few years rapid advances have been made in understanding the underlying genetic causes responsible for many of the intersex disorders. Conceptually, however, it is simplest to think of these causes in terms of the histology of the infant's gonads, which determines the prognosis with regard to fertility and pubertal development (Table 2). Certain gonads also carry an increased risk for malignant degeneration. A detailed discussion of the various disorders can be found in several excellent reviews.<sup>4,5</sup>

**TABLE 2.** Principal Causes of Ambiguous Genitalia According to Gonadal Histology

1. Ovary
CAH
Placental aromatase deficiency
Maternal source of virilization
2. Testis
Leydig cell hypoplasia
Testosterone biosynthesis defect
5- $\alpha$ -reductase deficiency
Androgen insensitivity
3. Ovary and testis
True hermaphroditism
4. Dysgenetic gonads
Gonadal dysgenesis
Denys-Drash and Frasier syndromes
Smith-Lemli-Opitz syndrome
Camptomelic dwarfism

### DECIDING THE SEX OF REARING

The decision as to the appropriate sex of rearing of a baby born with ambiguous genitalia is based on a number of considerations that have an impact on the infant's future.

### **Fertility Potential**

All female infants virilized because of CAH or maternal androgens are potentially fertile and should therefore be raised as girls. In most other intersex conditions the potential for fertility is either reduced or absent.

### **Capacity for Normal Sexual Function**

The size of the phallus and its potential to develop at puberty into a sexually functional penis are of paramount importance when one is considering male sex of rearing. Because of the difficulty assessing the potential for penile growth, particularly in those infants with partial androgen insensitivity, a trial of testosterone injections should be given in equivocal cases and the infant raised as a boy only when there is a very good response. The results of hypospadias repair by an experienced surgeon using current techniques are satisfactory, both cosmetically and functionally. The severity of the hypospadias should not, therefore, be a deciding factor in the sex of rearing. The presence of a capacious, low-lying vagina is advantageous if assignment as a female is being considered, but this alone is not of critical importance. A small, high-lying vagina presents more of a surgical challenge but this may be justified when such children are likely to be fertile.

### **Endocrine Function**

The ability of the gonads to produce appropriate hormones for sex of rearing is a factor in sex assignment. It is therefore advantageous to retain a gonad appropriate to the assigned sex if it is likely to function adequately. Among the intersex disorders the ovaries of virilized genetic females can be assumed to be normal. Ovaries of true hermaphrodites may also produce adequate levels of estrogen. However, the testes of true hermaphrodites and those of infants with mixed gonadal dysgenesis may initially show good function that declines during childhood, so that testosterone supplements may be necessary for the establishment of puberty or in adult life.<sup>6</sup>

### **Malignant Change**

The potential for malignant degeneration in a retained gonad with a Y chromosome-bearing cell line must be considered. Such changes are common in streak gonads in patients with a 46,XY cell line; streak gonads, therefore, should be removed at the time of diagnosis. Similarly, testes that show dysgenetic features on biopsy also need to be excised. The incidence of tumors is increased in histologically normal undescended testes, particularly those residing in the abdomen. However, a case can be made for retaining such a testis in patients with mild androgen insensitivity, true hermaphroditism, or mixed gonadal dysgenesis provided biopsy results show normal testicular tissue, the testis can easily be brought down into the scrotum, and the patient can be kept under long-term observation.

### **Testosterone Imprinting**

Historically, it has been assumed that the psychosexual development of infants with an intersex dis-

order is largely the result of rearing rather than intrinsic. However, in the past decade it has become apparent that testosterone imprinting of the fetal brain may play a role in determining male sexual orientation. Clinical studies in girls with CAH have confirmed the widely held impression that such children engage in more typically male-like behavior patterns than their unaffected peers<sup>7</sup> and occasionally may have difficulties with adjustment to their assigned gender.<sup>8</sup> Nonetheless, it appears that the majority of such girls do not overtly demonstrate problems with sexual identity, although scientific studies are sparse. Until further data become available, caution should be exercised when a recommendation is made that the sex of rearing should differ from the chromosomal sex. Such cases warrant careful individual consideration. Psychological counseling of affected individuals and their parents may be beneficial.

### **Timing of Surgery**

Infants raised as girls will usually require clitoral reduction which, with current techniques, will result not only in a normal-looking vulva but preservation of a functional clitoris. In girls with CAH, surgery can usually be performed once hormone replacement therapy is begun. A low-lying vagina can be exteriorized at the initial surgery, but in other cases this is best deferred until 1 year of age and often later. Additional surgery is often necessary. The testes should be removed soon after birth in infants with partial androgen insensitivity or testicular dysgenesis in whom a very small phallus mandates a female sex of rearing. In boys, an undescended testis that is to be retained is best brought down into the scrotum at the time of initial gonadal biopsy. Correction of chordee and urethroplasty in boys with hypospadias is usually performed between 6 and 18 months of age, usually in 1 stage as an outpatient procedure.

### **FOLLOW-UP**

Because of remaining uncertainties with regard to the long-term psychological and physical aspects of treatment among these patients, ongoing counseling of the parents and the affected child is advisable. Although it appears that most individuals are able to function in the normal range and are well-adjusted, few studies have been done that address the social, psychological, and sexual outcomes for affected adolescents and adults. There has been considerable debate about the appropriate gender assignment of newborns with the most extreme forms of genital ambiguity, with some suggesting that the current early surgical treatment be abandoned in favor of allowing the affected person to participate in gender assignment at a later time.<sup>9</sup> Although certain affected individuals will have conflicts between their psychosexual orientation and their genital appearance and function, the principles outlined in this review should minimize these problems when conducted by an appropriately constituted intersex team. When problems are apparent, help should be sought from psychologists, counselors, and other mental health professionals with experience in intersex dis-

orders. Some families may benefit from speaking to others who have had similar experiences. Most genetic and endocrine centers are able to refer families to appropriate support groups, or the family can contact the National Organization of Rare Disorders (800/999-6673) or visit their Web site (www.rarediseases.org) for more information.

### CONCLUSION

Although newborns with ambiguous genitalia are encountered rarely in a primary care pediatrician's practice, their diagnosis and prompt treatment require urgent medical attention. It is important to arrive at a definitive diagnosis so that an appropriate treatment plan can be developed, prognostic information shared, and accurate recurrence risk counseling communicated. The psychological distress that families feel during this time should be acknowledged. In some cases it will be necessary to assemble a team of specialists to perform these tasks in a timely, efficient manner. Pediatricians have a key role in this process by coordinating the diagnostic evaluation, helping families understand their child's medical condition, and maintaining open communication between the family and other health care team members.

#### COMMITTEE ON GENETICS, 1999–2000

Celia I. Kaye, MD, PhD, Chairperson  
Christopher Cunniff, MD  
Jaime L. Frias, MD  
John Moeschler, MD  
Susan R. Panny, MD  
Tracy L. Trotter, MD

#### LIAISON REPRESENTATIVES

Felix de la Cruz, MD, MPH  
National Institute of Child Health and Human Development  
Sherman Elias, MD  
American College of Obstetricians and Gynecologists  
James W. Hanson, MD  
American College of Medical Genetics  
Cynthia A. Moore, MD, PhD  
Centers for Disease Control and Prevention  
Michele Lloyd-Puryear, MD, PhD  
Health Resources and Services Administration

#### SECTION REPRESENTATIVE

Beth A. Pletcher, MD  
Section on Genetics and Birth Defects

#### CONSULTANTS

Ian Aaronson, MD  
Franklin Desposito, MD  
Peter Lee, MD  
Selma Witchel, MD

#### STAFF

Lauri Hall

#### SECTION ON ENDOCRINOLOGY, 1999–2000

Robert P. Schwartz, MD, Chairperson  
Inger L. Hansen, MD  
Francine Kaufman, MD  
Surendra Kumar Varma, MD  
Sharon E. Oberfield, MD  
Janet Silverstein, MD

#### LIAISON REPRESENTATIVES

Lynne L. Levitsky, MD  
Lawson Wilkins Pediatric Endocrine Society  
Michelle Reeves, RN, MN  
Pediatric Endocrinology Nursing Society

#### STAFF

Tiffany Varchetto, RN

#### SECTION ON UROLOGY, 1999–2000

Ronald Rabinowitz, MD, Chairperson  
John P. Gearhart, MD  
Rafael Gosalbez, Jr, MD  
James Mandell, MD  
Gordon Arthur McLorie, MD  
Craig Peters, MD  
Richard C. Rink, MD  
H. Gil Rushton, MD  
Mark Zaontz, MD

#### EX-OFFICIO

Stephen A. Kramer, MD

#### STAFF

Kathy Ozmeral

### REFERENCES

1. Aarskog D. Intersex conditions masquerading as simple hypospadias. *Birth Defects: Original Article Series*. 1971;7:122–130
2. Rajfer J, Walsh PC. The incidence of intersexuality in patients with hypospadias and cryptorchidism. *J Urol*. 1976;116:769–770
3. Lee PA, Mazur T, Danish R, et al. Micropenis 1. Criteria, etiologies and classification. *Johns Hopkins Med J*. 1980;146:156–163
4. Anhalt H, Neely EK, Hintz RL. Ambiguous genitalia. *Pediatr Rev*. 1996;17:213–220
5. Donahoe PK, Schnitzer JJ. Evaluation of the infant who has ambiguous genitalia, and principles of operative management. *Semin Pediatr Surg*. 1996;5:30–40
6. Aaronson IA. True hermaphroditism: a review of 41 cases with observations on testicular histology and function. *Br J Urol*. 1985;57:775–779
7. Hines M, Kaufman FR. Androgen and the development of human sex-typical behavior: rough-and-tumble play and sex of preferred playmates in children with congenital adrenal hyperplasia (CAH). *Child Dev*. 1994;65:1042–1053
8. Reiner WG. Sex assignment in the neonate with intersex or inadequate genitalia. *Arch Pediatr Adolesc Med*. 1997;151:1044–1045
9. Diamond M, Sigmundson HK. Management of intersexuality: guidelines for dealing with persons with ambiguous genitalia. *Arch Pediatr Adolesc Med*. 1997;151:1046–1050