

# AMERICAN ACADEMY OF PEDIATRICS

Committee on Bioethics

## Female Genital Mutilation

**ABSTRACT.** The traditional custom of ritual cutting and alteration of the genitalia of female infants, girls, and adolescents, referred to as female genital mutilation (FGM), persists primarily in Africa and among certain communities in the Middle East and Asia. Immigrants in the United States from areas where FGM is endemic may have daughters who have undergone a ritual genital procedure or may request that such a procedure be performed by a physician. The American Academy of Pediatrics (AAP) believes that pediatricians and pediatric surgical specialists should be aware that this practice has serious, life-threatening health risks for children and women. The AAP opposes all forms of FGM, counsels its members not to perform such ritual procedures, and encourages the development of community educational programs for immigrant populations.

---

ABBREVIATIONS. FGM, female genital mutilation; AAP, American Academy of Pediatrics.

---

Ritual cutting and alteration of the genitalia of female infants, girls, and adolescents has been a tradition since antiquity. It persists today primarily in Africa and among small communities in the Middle East and Asia. The spectrum of these genital procedures has been termed female circumcision, or more frequently, female genital mutilation (FGM) as a collective name describing several different traditional rituals that emphasizes the physical disfigurement associated with the practice. It is estimated that at least 100 million women have undergone FGM and that between 4 and 5 million procedures are performed annually in female infants and girls, with the most severe types of FGM carried out in Somalian and Sudanese populations.<sup>1,2</sup> Pediatricians, therefore, may encounter patients who have undergone these procedures and pediatric surgeons and pediatric urologists may be requested by patients or by the parents of patients to perform surgery considered a ritual genital operation.

During the past 2 decades several international and national humanitarian and medical organizations have drawn worldwide attention to the physical harms associated with FGM. The World Health Organization and the International Federation of Gynecology and Obstetrics have opposed FGM as a medically unnecessary practice with serious, poten-

tially life-threatening complications.<sup>3,4</sup> The American College of Obstetricians and Gynecologists and the College of Physicians and Surgeons of Ontario, Canada, also opposed FGM and advised their members not to perform these procedures.<sup>5,6</sup> In 1995 the Council on Scientific Affairs of the American Medical Association recommended that all physicians in the United States strongly denounce all medically unnecessary procedures to alter female genitalia, as well as promote culturally sensitive education about the physical consequences of FGM.<sup>7</sup>

FGM is illegal and subject to criminal prosecution in several countries, including Sweden, Norway, Australia, and the United Kingdom.<sup>8,9</sup> In 1996 the Congress of the United States enacted legislation to criminalize the performance of FGM by practitioners on female infants and children or adolescents younger than 18 years and to develop educational programs at the community level and for physicians about the harmful consequences of the practice.<sup>10</sup>

The American Academy of Pediatrics (AAP) encourages its members to: 1) become informed about the major types of FGM and their complications; 2) be able to recognize the physical signs of FGM; 3) be aware of the cultural and ethical issues associated with FGM; 4) develop a compassionate educational approach for patients who have undergone or who request such a procedure; and 5) decline performing all medically unnecessary procedures to alter female genitalia.

### TYPES OF FEMALE GENITAL MUTILATION

FGM is most often performed between the ages of 4 and 10 years, although in some communities it may be practiced on infants or postponed until just before marriage.<sup>11</sup> Typically a local village practitioner, lay person, or midwife is engaged for a fee to perform the procedure, which is done without anesthesia using a variety of instruments, such as knives, razor blades, broken glass, or scissors. In developed countries physicians may be sought to perform FGM under sterile conditions with the use of anesthesia. Figure 1 shows the normal genital anatomy of a prepubertal female. The various ritual genital practices are classified into four types based on the severity of structural disfigurement.<sup>12</sup>

Type I FGM, often termed clitorectomy, involves excision of the skin surrounding the clitoris with or without excision of part or all of the clitoris (Fig 2). When this procedure is performed in infants and young girls, a portion of or all of the clitoris and surrounding tissues may be removed. If only the clitoral prepuce is removed, the physical manifesta-

---

This statement has been approved by the Council on Child and Adolescent Health.

The recommendations in this statement do not indicate an exclusive course of treatment or serve as a standard of medical care. Variations, taking into account individual circumstances, may be appropriate.

PEDIATRICS (ISSN 0031 4005). Copyright © 1998 by the American Academy of Pediatrics.

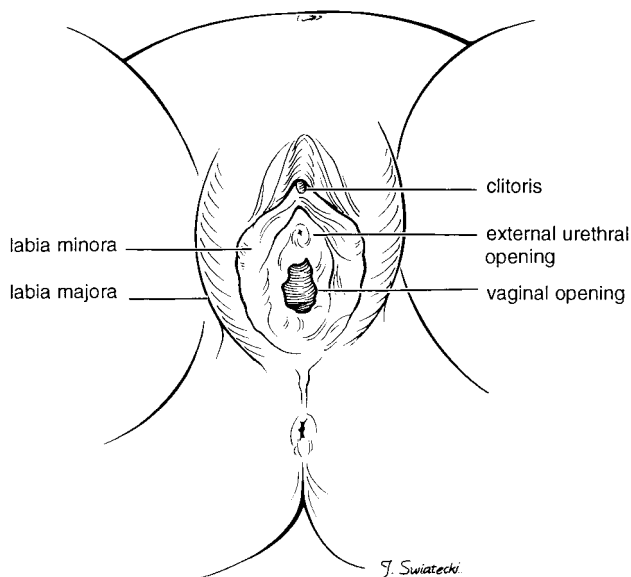


Fig 1. Normal female genital anatomy.

tion of Type I FGM may be subtle, necessitating a careful examination of the clitoris and adjacent structures for recognition.

Type II FGM, referred to as excision, is the removal of the entire clitoris and part or all of the labia minora (Fig 3). Crude stitches of catgut or thorns may be used to control bleeding from the clitoral artery and raw tissue surfaces, or mud poultices may be applied directly to the perineum. Patients with Type II FGM do not have the typical contour of the anterior perineal structures resulting from the absence of the labia minora and clitoris. The vaginal opening is not covered in the Type II procedure.

Type III FGM, known as infibulation, is the most severe form in which the entire clitoris and some or all of the labia minora are excised, and incisions are made in the labia majora to create raw surfaces (Fig 4). The labial raw surfaces are stitched together to cover the urethra and vaginal introitus, leaving a small posterior opening for urinary and menstrual flow. In Type III FGM, the patient will have a firm band of tissue replacing the labia and obliteration of the urethra and vaginal openings.

Type IV includes different practices of variable severity including pricking, piercing or incision of the clitoris and/or labia; stretching of the clitoris and/or labia; cauterization of the clitoris; and scraping or introduction of corrosive substances into the vagina.

The physical complications associated with FGM may be acute or chronic. Early, life-threatening risks include hemorrhage, shock secondary to blood loss or pain, local infection and failure to heal, septicemia, tetanus, trauma to adjacent structures, and urinary retention.<sup>13,14</sup> Infibulation (Type III) is often associated with long-term gynecologic or urinary tract difficulties. Common gynecologic problems involve the development of painful subcutaneous dermoid cysts and keloid formation along excised tissue edges. More serious complications include pelvic infection, dysmenorrhea, hematocolpos, painful intercourse,

infertility, recurrent urinary tract infection, and urinary calculus formation. Pelvic examination is difficult or impossible for women who have been infibulated, and vaginal childbirth requires an episiotomy to avoid serious vulvar lacerations.

Less well-understood are the psychological, sexual, and social consequences of FGM, because little research has been conducted in countries where the practice is endemic.<sup>15</sup> However, personal accounts by women who have had a ritual genital procedure recount anxiety before the event, terror at being seized and forcibly held during the event, great difficulty during childbirth, and lack of sexual pleasure during intercourse.<sup>16</sup> Some women have no recollection of the event, particularly if it was performed in infancy, while others deny that the procedure has had any negative effect on their health or sexual life.

### CULTURAL AND ETHICAL ISSUES

FGM has been documented in individuals from many religions, including Christians, Muslims, and Jews. Some proponents of the practice claim that it is required by the Islamic faith. However, scholars and theologians of Islam state that female circumcision is not prescribed by their religious doctrine, emphasizing that the procedure is almost never performed in many major Muslim countries such as Saudi Arabia, Iran, and Pakistan.<sup>17</sup>

Kopelman<sup>18</sup> has summarized four additional reasons proposed to explain the custom of FGM: 1) to preserve group identity; 2) to help maintain cleanliness and health; 3) to preserve virginity and family honor and prevent immorality; and 4) to further marriage goals, including enhancement of sexual pleasure for men. Preservation of cultural identity has been noted by Toubia<sup>19</sup> to be of particular importance for groups who have previously faced colonialism and for immigrants threatened by a dominant culture. FGM is endemic in poor societies where marriage is essential to the social and economic se-

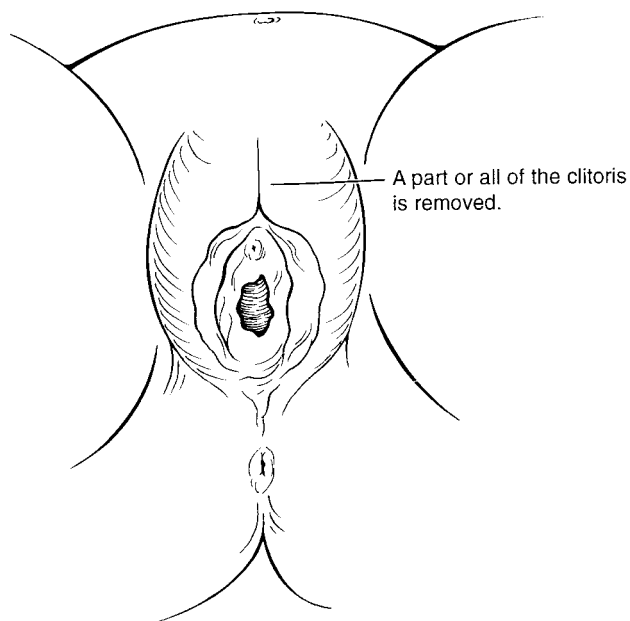


Fig 2. Type I female genital mutilation.

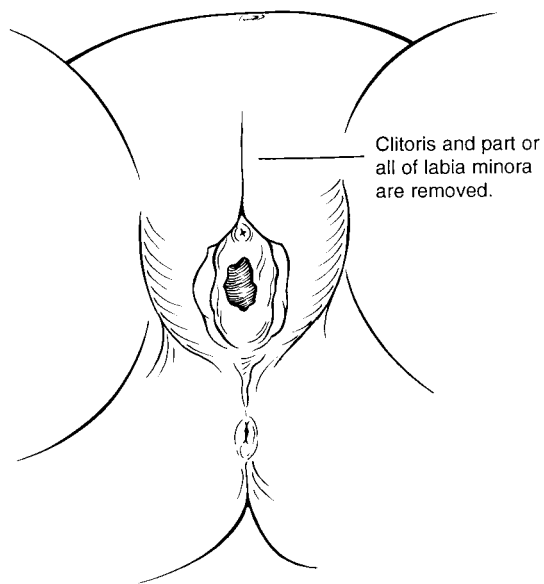


Fig 3. Type II female genital mutilation.

curity for women. FGM becomes a physical sign of a woman's marriageability, with social control exercised over her sexual pleasure by clitorrectomy and over reproduction by infibulation.

When parents request a ritual genital procedure for their daughter, they believe that it will promote their daughter's integration into their culture, protect her virginity, and thereby guarantee her desirability as a marriage partner. Parents are often unaware of the harmful physical consequences of the custom, because the complications of FGM are attributed to other causes and rarely discussed outside of the family.<sup>20</sup> Furthermore, parents may feel obligated to request the procedure because they believe their religion requires female genital alteration.<sup>21</sup>

The physical burdens and potential psychological harms associated with FGM violate the principle of nonmaleficence, a commitment to avoid doing harm, and disrupt the accepted norms inherent in the patient-physician relationship, such as trust and the promotion of good health. More recently, FGM has been characterized as a practice that violates the right of infants and children to good health and well-being, part of a universal standard of basic human rights.<sup>22</sup>

Although pediatricians and pediatric surgical specialists may believe that refusal to perform FGM may represent ethnic and Eurocentric cultural imperialism, protection of the physical and mental health of girls should be the overriding concern of the health care community. Humanitarian organizations led by women from cultures in which FGM is practiced have adopted a strong position against the procedure because of its serious physical and psychological consequences.

#### EDUCATION OF PATIENTS AND PARENTS

An educational program about FGM requires, above all, sensitivity to the cultural background of the patient and her parents and an appreciation of the significance of this custom in their tradition.<sup>23</sup>

Objective information should include a detailed explanation of female genital anatomy and function, as well as a thorough review of the lifelong physical harms and psychological suffering associated with FGM. It should be emphasized that many countries in Africa have supported efforts to educate the public about the serious negative health effects of FGM, and that prominent physicians from Africa are advocates for the elimination of these practices because of their adverse consequences. Pediatricians and pediatric surgical specialists who care for patients from populations known to commonly practice FGM, such as Somalian, Ethiopian, Eritrean, and Sudanese communities, should be aware of local counseling centers. Successful educational programs typically require the active involvement and leadership of immigrant women, whose experience and knowledge can address the health, social status, and legal aspects of FGM.

Some physicians, including pediatricians, who work closely with immigrant populations in which FGM is endemic, have voiced concern about the adverse effects of criminalization of the practice on educational efforts.<sup>24</sup> These physicians emphasize the significance of a ceremonial ritual in the initiation of the girl or adolescent as a community member, and advocate a lesser procedure, such as pricking or incision of the clitoral skin, as often sufficient to satisfy cultural requirements. Pediatricians and pediatric surgical and urologic surgeons who are contemplating performing such a procedure should consider their role in perpetuating this social practice with its cultural implications for the status of women. It is also unclear whether performing such lesser procedures would be exempt from federal criminal laws.

Efforts should be made to use all available educational and counseling resources to dissuade parents from seeking a ritual genital procedure for their daughter. In those circumstances in which an infant, child, or adolescent appears to be at risk of FGM, the AAP

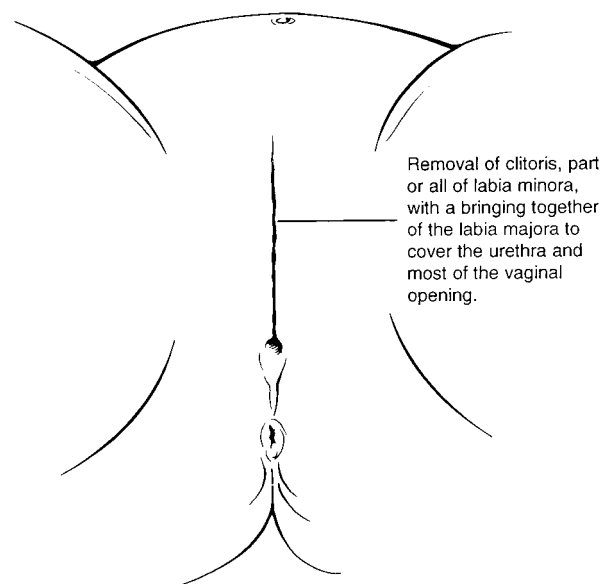


Fig 4. Type III female genital mutilation.

recommends that its members educate and counsel the family about the health effects of FGM. Parents should be reminded that performing FGM is illegal and constitutes child abuse in the United States.

### RECOMMENDATIONS

The American Academy of Pediatrics:

1. Opposes all forms of female genital mutilation (FGM).
2. Recommends that its members actively seek to dissuade families from carrying out FGM.
3. Recommends that its members provide patients and their parents with compassionate education about the physical harms and psychological risks of FGM.
4. Recommends that its members decline to perform any medically unnecessary procedure that alters the genitalia of female infants, girls, and adolescents.

COMMITTEE ON BIOETHICS, 1997 TO 1998

Joel E. Frader, MD, Chairperson  
Jeffrey R. Botkin, MD, MPH  
Kathryn L. Moseley, MD  
Robert M. Nelson, MD  
Benjamin S. Wilfond, MD

LIAISON REPRESENTATIVES

Alessandra Kazura, MD  
American Academy of Child & Adolescent  
Psychiatry  
Watson A. Bowes, MD  
American College of Obstetricians & Gynecologists  
Ernest Krug III, MD  
American Board of Pediatrics

SECTION LIAISON

Donna A. Caniano, MD  
Section on Surgery

LEGAL CONSULTANT

Nancy M. P. King

### REFERENCES

1. Kouba LJ, Muasher J. Female circumcision in Africa: an overview. *African Studies Rev.* 1985;28:95-110
2. Ntiri DW. Circumcision and health among rural women of southern Somalia as part of a family life survey. *Health Care Women Int.* 1993;14: 215-226
3. *UN Agencies Call for End to Female Genital Mutilation.* Geneva, Switzerland: World Health Organization; April 9, 1997
4. World Health Organization, International Federation of Gynecology and Obstetrics. Female circumcision. *Eur J Obstet Gynecol Reprod Biol.* 1992;45:153-154
5. American College of Obstetricians and Gynecologists. *Committee Opinion—Female Genital Mutilation.* Washington, DC: American College of Obstetrics and Gynecology; January 1995:151
6. The College of Physicians and Surgeons of Ontario. *New Policy—Female Circumcision, Excision and Infibulation.* Toronto, Canada: The College of Physicians and Surgeons of Ontario; March 1992:25
7. Council on Scientific Affairs. Female genital mutilation. *JAMA.* 1995; 274:1714-1716
8. *Act Prohibiting Genital Mutilation of Women;* 1982;316
9. Appendix I: Elizabeth II Prohibition of Female Circumcision Act; 1985
10. Sections 664 and 665 of the Illegal Immigration Reform and Immigrant Responsibility Act of 1996, Division C, *Omnibus Consolidated Appropriations Act for Fiscal Year 1997.* Pub L No. 104-208; Sept 30, 1996
11. Toubia N. Female circumcision as a public health issue. *N Engl J Med.* 1994;331:712-716
12. World Health Organization. *Female Genital Mutilation.* Geneva, Switzerland: World Health Organization; April 1997
13. Institute for Development Training. *Health Effects of Female Circumcision.* Chapel Hill, NC: Institute for Development Training; 1986
14. Armstrong S. Female circumcision: fighting a cruel tradition. *New Scientist.* 1991;129:42-48
15. Dorkenoo E, Elworthy S. *Female Genital Mutilation. Proposals for Change.* London, England: Minority Rights Group; 1992
16. Crossette B. Female genital mutilation by immigrants is becoming cause for concern in the US. *New York Times.* December 10, 1995:18
17. International Association for Maternal and Neonatal Health. Female circumcision. *Mother and Child International Newsletter.* 1991;17:4-5
18. Kopelman LM. Female circumcision/genital mutilation and ethical relativism. *Second Opinion.* 1994;20:55-71
19. Toubia N. *Female Genital Mutilation: A Call for Global Action.* New York, NY: RAINBo; 1995
20. Female circumcision/genital mutilation. *Forward News.* 1990;2:1-10
21. Lightfoot-Klein H. *Prisoners of Ritual—An Odyssey Into Female Genital Circumcision in Africa.* New York, NY: Haworth Press; 1989
22. James SA. Reconciling international human rights and cultural relativism: the case of female circumcision. *Bioethics.* 1994;8:1-26
23. Lane SD, Rubinstein RA. Judging the other—responding to traditional female genital surgeries. *Hastings Cent Rep.* 1996;26:31-40
24. Kelley T. Doctor fights ban on circumcising girls. *Seattle Times.* June 6, 1996:B3